

# Human Penile Ossification

Noor Khan Lakhnana<sup>1</sup> and Naghmi Asif<sup>2</sup>

<sup>1</sup>Professor/HOD, Department of Pathology, Al-Nafees Medical College, Islamabad

<sup>2</sup>Assistant Professor, Department of Pathology, Islamabad Medical & Dental College, Islamabad  
(<sup>2</sup>Bahria University, Islamabad)

## Abstract

Ossification in the human penis is a rare condition and very few cases have previously been reported. Among several conditions that have been correlated with this problem the most frequent is Peyronie's disease. Other causes include trauma, end stage renal disease, syphilis, gonorrhoea and metabolic disorders like gout and diabetes. In all these conditions, human penile ossification appears to be a metaplastic bone formation process. In view of this, the following case is worthy of record.

## Introduction

Ossification occurring in the human penis is exceedingly rare, with fewer than 40 cases reported.<sup>1</sup> Etiology of bone formation in human penis is not clear. Various causes have been proposed.<sup>2</sup> It is usually an acquired condition. Congenital human penile ossification is extremely rare, with only one reported case in a 5-year-old boy and it was associated with other congenital anomalies such as cleft scrotum.<sup>3</sup> Peyronie's disease has been described as the most common cause for ossification of the penis. It is a chronic inflammation of tunica albuginea that leads to penile fibrosis. The hardened plaque reduces flexibility and leads to a penile bend or curvature during erection. Less common causes include local trauma to the penis (including sexual trauma), chronic hemodialysis in patients with end-stage renal disease, chronic inflammatory states as syphilis and gonorrhoea, and with general metabolic disorders such as gout and diabetes.<sup>4</sup> It is not well understood what initiates the ossification. Probably fibrosis starts initially and this with continuous stimulation leads to proliferation and metaplasia.<sup>5</sup> Diagnosis is confirmed on radiological and histopathological findings.

## Case Report

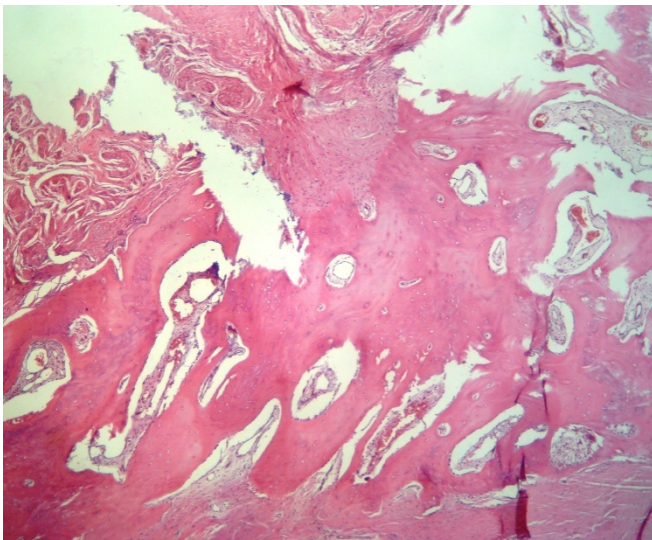
A 55-year-old man presented with a one-year history of slight pain upon erection and during intercourse.

He also complained of hardness in the shaft of the penis. There was no history of trauma, metabolic disorder or erectile impotency. The results of routine laboratory evaluations were normal. Examination of the penis revealed a fixed hard mass extending over the proximal third of the penile shaft, measuring 3.0 x 3.5 x cm in subcutaneous tissue (involving the corporal sponge) without surface extension to skin. No deformity or change in curvature of penis was observed. The mass was excised surgically and sent for histopathological examination. A gross examination of the specimen revealed multiple fragments of soft and bony tissue measuring 3x3 cm<sup>3</sup> collectively. Whole of the tissue was submitted i.e. soft tissue as such and bony tissue (after decalcification), for processing and microscopic examination. Histological examination revealed cancellous bone surrounded by dense collagen tissue.

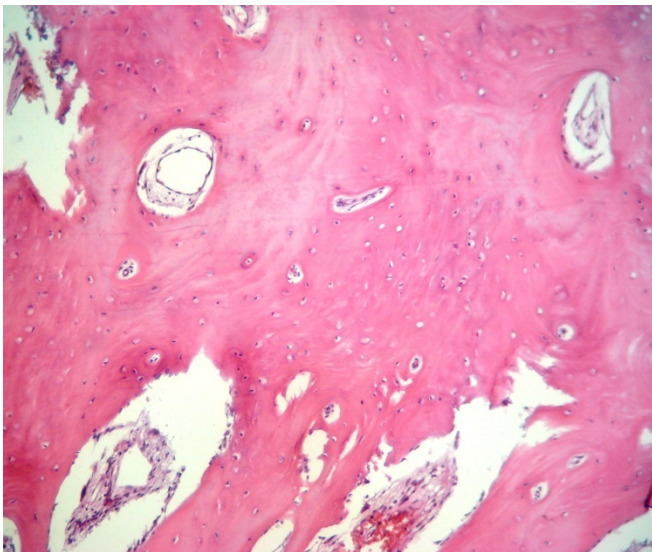
## Discussion

The earliest case of penile ossification (PO) in the literature was reported by McClellan in 1827, who described a case of ossification along the full length of penis. In the vast majority of cases the occurrence of ossification in the penis is the result of local trauma or a late manifestation of Peyronie's disease. Post-traumatic calcification in the penis is relatively uncommon. Hecker (1844) described a case in which severe trauma to the penis was followed four months later by ossification. In 1899 Chetwood reported a second case of ossification of corpora cavernosa in a postmortem specimen of a 55-year-old diabetic man. In 1933, Vermooten described a 19-year-old male in whom a bony mass had developed in the glans penis.<sup>4</sup> The patient also had a gunshot wound at that site 3 months previously. Presumably ossification had taken place in fibrosis resulting from this injury. A fourth case of penile ossification was reported by Eglitis in 1953. In this case, microscopic examination of sections taken from a grossly normal penis at autopsy

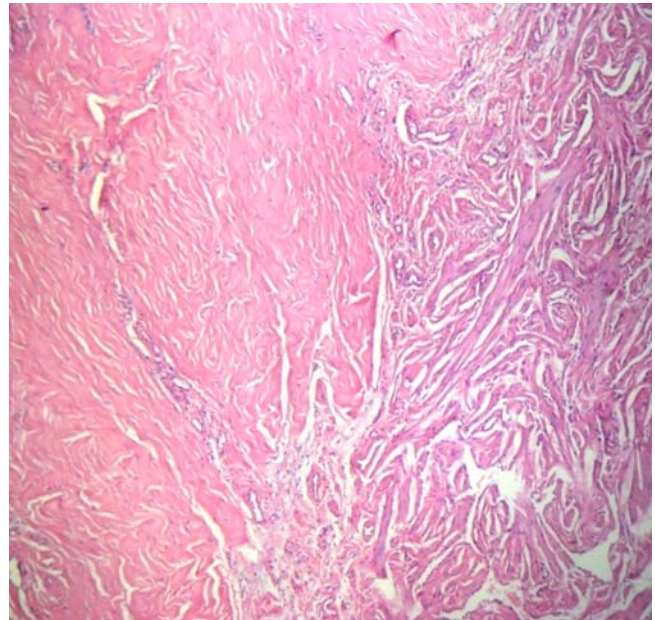
identified bony plaques in the subcutaneous tissue, with no clues as to the etiology of this ossification. In 1962, Elliot and Fischerman reported a case of a 68-year-old man who presented with a 5-cm bone in his corpus spongiosum which required surgical excision. The man was previously diagnosed with gout; however, the bone formation was thought to be unrelated.<sup>1</sup> Subsequent to these rare cases of penile ossification reported in the early literature, other cases of localized penile ossification secondary to Peyronie's disease have been reported.<sup>6</sup>



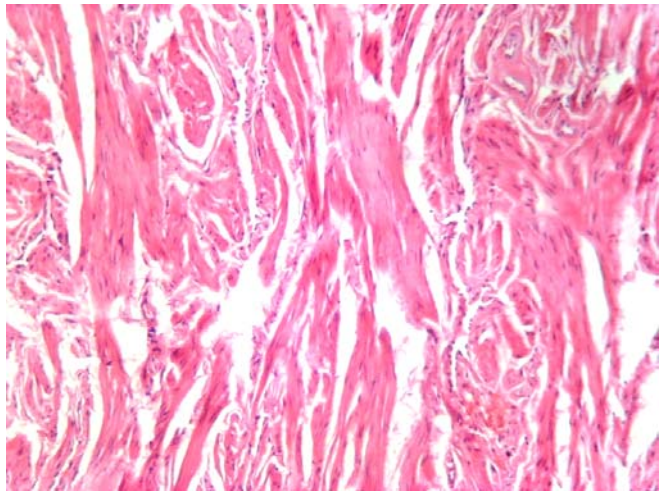
**Figure 1. Bony tissue with intervening fibrous tissue. (H&E stain 10x10)**



**Figure 2. Bony tissue at higher magnification. (H&E stain 40x10)**



**Figure 3: Fibrous tissue (left) with penile tissue (right) (H&E 10X10)**



**Figure 4. Fibrous tissue and penile tissue (H&E stain 40x10)**

Peyronie's disease, the condition known as plastic induration of the penis and is referred to as one of the common causes for penile ossification.<sup>6</sup> It is most commonly seen in the fifth and sixth decades of life<sup>7,8</sup> and the initial presenting symptoms are usually those of painful penile erections accompanied by curvature; the deflection is usually dorsal. The condition is characterized by the formation of one or more fibrous plaques usually between Buck's fascia and the tunica albuginea of the corpora cavernosa. Ulceration and

malignant transformation have not been observed, but occasionally calcium or bone formation occurs. Microscopically, no evidence of inflammation or infiltration can be found. There are few vessels and many spindle-like cells, but compact bundles of connective tissue compose the chief architecture. The etiology of the disease remains obscure. Shehzad et al reported a case of Peyronie's disease in 40 years old man who presented with plaque on penile shaft with penile deformity and painful erection.<sup>9</sup> Another case was reported in a forty-five year old man who noticed a rod-like mass at the base of penis which existed since puberty but he had no symptoms associated with erectile dysfunction. CT scan confirmed the diagnosis of PO. Since he had no erectile dysfunction, he refused further tests.<sup>10</sup> In most cases, both radiological and histopathological investigations confirm the diagnosis.<sup>11</sup>

Apart from cases of Peyronie's disease, one or more bony plaques have rarely been demonstrated in the human penis; these have been likened to the os penis of animals. It is well known that many animals normally possess a bone in the penis. In most reported cases PO is acquired during adult life and in majority of them this followed trauma such as kick or sexual trauma. No case reports of PO with squamous cell carcinoma have been reported. However association of venereal diseases and metabolic disorders such as diabetes mellitus and gout has been reported.

Other causes such syphilis, gout, diabetes, arthritis and vitamin E deficiency have all been incriminated as etiological factors. The significance of the occasional presence of bone tissue in the human penis unrelated to trauma or Peyronie's disease remains unclarified. Bone formation in human penis probably occurs as a metaplastic process. The fibroblastic tissue in healing

traumatic lesion and in Peyronie's disease may provide a fertile soil for metaplastic bone formation.<sup>12</sup>

## References

1. Edhem I, Yilmaz E, Barazani Y and Tareen B. Penile ossification: A traumatic event or evolutionary throwback? Case report and review of the literature. *CUAJ* 2013;7(1-2):E112-114
2. Liguori G, Traombetta C, Savoca G and Bussani R. Penile Ossification: a model radiological presentation. *Bj Urology* 1998; 81:334.
3. Champion RH, Wegrzyn J. Congenital os penis. *J Urol* 1964;91:663- cited by Ibrahim Edhem Yilmaz E, Barazani Y and Tareen B. Penile ossification: A traumatic event or evolutionary throwback? Case report and review of the literature. *CUAJ* 2013;7(1-2):E112-114
4. Sarma DP, Weilbaecher TG. Human Os Penis. *Urology* 1990; 35: 349-350
5. Motiwala HG, Rajyaguru DA, Visanae KN, Shan SC, Patel PC. Human Penile Ossification. *Br J Urology* 1992; 70:569-70
6. Jalkut M, Gonzalez-Cadavid N, Rajfer J. New discoveries in the basic science understanding of Peyronie's disease. *Curr Urol Rep.* 2004; 5(6):478-84.
7. Davis CJ. The microscopic pathology of Peyronie's disease. *J Urol* 1997; 157: 282-4.
8. Z Amin, U Patel, EP Friedman, et al. Colour Doppler and duplex ultrasound assessment of Peyronie's disease in impotent men. *The British Journal of Radiology* 1993; 66(785):398-402.
9. Shehzad A, Rehman S, Shaheen S and Khan WA et al. Penile fibromatosis (Peyronie's disease): a rare disorder. *Journal of Pakistan Association of Dermatologists* 2008; 18: 56-59.
10. Ersay AR, Alan C, Koçoğlu H. Human os penis. *Central European Journal of Urology* 2010;63(4):203-204.
11. de Arruda HO, de Lima H, Ortiz V. Human penile ossification: case report. *Sao Paulo Med J.* 2007;125(2):124-5
12. Guileyardo JM, Sarma DP. Human penile ossification. *Urology* 1982; 20 (4): 428-429